



A 5-year randomized clinical trial comparing minimally with moderately rough implants in patients with severe periodontitis

Magalie Raes¹  | Rutger D'hondt¹ | Wim Teughels¹  | Wim Coucke² | Marc Quirynen¹

¹Departments of Oral Health Sciences and Periodontology, KU Leuven & University Hospitals Leuven, Leuven, Belgium

²Department of Clinical Biology, Scientific Institute of Public Health, Brussels, Belgium

Correspondence

Wim Teughels, KU Leuven, Faculty of Medicine, Department of Oral Health Sciences, Periodontology Section, Leuven, Belgium.

Email: Wim.Teughels@med.kuleuven.be

Funding information

The department of Periodontology owns a research chair from Dentsply Sirona and Intra-Lock and has an educational grant from Nobel Biocare. All fixtures, healing abutments and final abutments were provided by Nobel Biocare, AB. The study was partially supported by a research grant from Nobel Biocare.

Abstract

Aim: To compare the clinical and microbiological performance of minimally and moderately rough implants in patients with a history of severe periodontitis.

Material and Methods: Forty-eight minimally (Turned surface [Tur]) and moderately (TiUnite surface [TiU]) rough implants were placed in eighteen patients according to a split-mouth protocol. Marginal bone loss, probing pocket depth (PPD), clinical attachment level (CAL), and bleeding on probing (BoP) were recorded, and microbial samples were analysed by means of quantitative PCR.

Results: The amount of bone loss over the 5-year period tended to be lower along Tur when compared with that of TiU surfaces (1.0 versus 1.7 mm, $p = .06$). Although the clinical outcomes tended to be better for Tur surfaces, there were no significant differences between both surfaces in mean PPD (Tur: 3.1 versus TiU: 4.2 mm, $p = .09$) or CAL (Tur: 0.5 versus TiU: 1.7 mm, $p = .06$). More bone loss and deeper pockets were recorded for partially than for fully edentulous patients. The cumulative survival rate at 5-year follow-up was 95.8% for Tur, and 100% for TiU surface implants. No significant differences were found between the surfaces in counts for key pathogens.

Conclusion: In patients with a history of severe periodontitis minimally rough implants showed more favourable clinical parameters after 5 years of loading, when compared with moderately rough implants.

KEYWORDS

bone loss, implant failures, implant surface roughness, peri-implantitis, surface characteristics

1 | INTRODUCTION

Most currently used implants have a moderately rough implant surface, based on the classification by Albrektsson and Wennerberg (2004). This classification considers implant surfaces as minimally rough when the average roughness (Sa) values lie between 0.5 and 1.0 μm , moderately rough when Sa values lie between 1 and 2 μm , and rough when Sa values exceed 2.0 μm . The TiU from Nobel Biocare AB is a moderately rough surface with an Sa value

of 1.1 and a developed interfacial area ratio of 37% (Wennerberg & Albrektsson, 2010).

Roughened surfaces were introduced to enhance the clinical outcome of implant therapy by increasing osteoconduction and inducing osteogenesis. Both animal and human histological studies have shown increased bone-to-implant contact during and after initial healing for rougher implant surfaces (Bernard, Szmukler-Moncler, Pessotto, Vazquez, & Belser, 2003; Koh, Yang, Han, Lee, & Kim, 2009; Polizzi, Gualini, & Friberg, 2013). Most of the studies that

compared moderately to minimally rough implant surfaces applied an immediate-loading protocol, and found an enhanced outcome for the moderately rough surfaces (Alsaadi et al., 2008; Arnhart et al., 2013; Jungner, Lundqvist, & Lundgren, 2005; Rocci et al., 2013; Vandeweghe, Ferreira, Vermeersch, Mariën, & De Bruyn, 2016). Glauser, Schüpbach, Gottlow, and Hämmerle (2005) compared both surfaces histologically, and observed a longer junctional epithelium on the minimally rough surfaces versus a wider connective tissue seal around moderately rough implants.

However, in the oral environment, rougher implant surfaces are known to facilitate biofilm formation and maturation, increasing the risk of peri-implantitis (Lang & Berglundh, 2011; Quirynen & Bollen, 1995; Teughels, Van Assche, Sliepen, & Quirynen, 2006). Today, it is generally accepted that low surface-free energy materials, with reduced surface roughness, limit plaque accumulation in vivo. The influence of surface roughness on plaque accumulation is more crucial than the surface-free energy or the electrical charge (Amoroso et al. 2006; Bürgers et al., 2010; Quirynen & Bollen, 1995; Teughels et al., 2006). Subgingivally, surfaces with a Ra of 0.8 harboured, for example, 25× more bacteria, compared to surfaces with a Ra of 0.3 µm, with a slightly lower density of cocci (Quirynen et al. 1993). A systematic review showed a 20% reduced risk of peri-implantitis for smoother surfaces over a 3-year period when compared with that for rougher surfaces (Esposito, Grusovin, Coulthard, Thomsen, & Worthington, 2005). Also, if left untreated, peri-implant disease seems to progress faster around medium-rough surfaces than around smooth surfaces, at least in the canine dog model (Berglundh, Gottfredsen, Zitzmann, Lang, & Lindhe, 2007).

Implant therapy has been proven an effective treatment for replacing teeth, both in fully and in partially edentulous patients (Hultin, Fischer, Gustafsson, Kallus, & Klinge, 2000; Lindquist, Carlsson, & Jemt, 1996; Quirynen et al., 2005). When examining success rates for implant therapy in partially versus fully edentulous patients who have lost their teeth due to periodontitis, there are indications that partially edentulous patients are at greater risk of developing peri-implant disease. This could be due to remaining pockets around teeth that might serve as reservoirs for periopathogens. These pathogens could then colonize the newly formed pockets around the implants (Aoki et al., 2012; Apse, Ellen, Overall, & Zarb, 1989; Fürst, Salvi, Lang, & Persson, 2007; Mombelli, Marxer, Gaberthüel, Grunder, & Lang, 1995; Mombelli, Müller, & Cionca, 2012; Quirynen et al., 2005; Renvert & Quirynen, 2015). However, it has been shown that full-mouth tooth extraction, while causing a significant reduction in the amount of periodontal pathogens in the mouth, is not able to eradicate these pathogens completely (Quirynen & Van Assche, 2011). This would mean that even after full-mouth extraction, colonization of the pristine peri-implant pockets can occur. There are also indications that implants placed in patients with a history of periodontitis have a greater risk of developing peri-implant disease and show more peri-implant bone loss (Daubert, Weinstein, Bordin, Leroux, & Flemming, 2015; Karoussis, Kotsovilis, & Fourmousis, 2007; Ong et al., 2008; Pjetursson et al., 2012;

Clinical Relevance

Scientific rationale for the study: It is still an open question which implant surface offers the best outcomes in patients with a history of severe periodontitis. Previous studies indicated that increased implant-surface roughness improves osseointegration but encourages pathogen colonization. This study investigated the clinical and microbiological outcome of minimally and moderately rough-surface implants in patients with a history of periodontitis over 5 years.

Principle finding: Most clinical outcomes were more favourable for minimally rough implants. Partially edentulous patients were at higher risk of developing peri-implantitis than fully edentulous patients.

Practical implications: These data seem to indicate that teeth with remaining periodontitis might jeopardize the long-term success of moderately rough implants.

Renvert & Persson, 2009; Renvert & Polyzois, 2015; Renvert & Quirynen, 2015; Rocuzzo, Bonino, Aglietta, & Dalmasso, 2012; Van der Weijden, van Bommel, & Renvert, 2005; Vandeweghe et al., 2016). This risk, however, reduces significantly when the patient is enrolled in a proper maintenance programme (Hardt, Gröndahl, Lekholm, & Wennström, 2002; Mishler & Shiau, 2014; Pjetursson et al., 2012; Quirynen, Abarca, Van Assche, Nevins, & van Steenberghe, 2007; Rinke, Ohl, Ziebolz, Lange, & Eickholz, 2011).

The goal of this study was to present 5-year follow-up clinical and microbiological data highlighting the differences between the minimally rough Turned surface (Tur) and the moderately rough TiU surface (TiU), both with the same macro-model (the Brånemark MK III implant; Nobel Biocare AB), in patients with a history of severe periodontitis. To evaluate differences between partially and fully edentulous patients, two subgroups were considered.

2 | MATERIAL AND METHODS

2.1 | Study protocol

This prospective randomized clinical trial (RCT) with a split-mouth concept initially enrolled 18 patients (divided into two subgroups: the full edentulous group in which all teeth had been extracted at least 6 months prior to implant placement and the partial edentulous group with teeth in the antagonistic jaw having remaining pockets (4–6 mm, for more details see Van Assche et al., 2012; Nicu, Van Assche, Coucke, Teughels, & Quirynen, 2012). These patients were not willing to undergo any additional, surgical therapy to treat these remaining pockets or had irrational to treat teeth, but refused the extraction of these teeth.

All patients had a history of severe periodontitis and had lost teeth primarily because of periodontal disease. Per patient, ≥ 2 Tur and ≥ 2 TiU implants were randomly alternated (computer randomization program). The healing abutments as well as the final abutments had a turned surface for the Tur implants, but a TiU surface for the TiU implants, respectively. Because the abutments are partially visible, the clinical parameters could not be recorded blinded.

This trial was conducted in accordance with the Declaration of Helsinki. The protocol was approved by the Ethical committee of the Catholic University Leuven (Leuven, Belgium), and informed consent was obtained from all participants.

This 5-year report includes 15 of the initial group 18 patients, 1 patient passed away, and 2 patients were no longer able to visit the clinic (physical reasons).

2.2 | Surgical procedure

All implants had the Brånemark MK III (Nobel Biocare AB) macro design, with either the TiU or the Tur surface. A conservative loading protocol was used (3 months submerged healing for the mandible, 6 months for the maxilla). For more details, see Van Assche et al., 2012.

2.3 | Radiographic examination (primary outcome variable)

Mesial and distal bone levels were measured relative to the implant shoulder, which served as the reference. Intra-oral radiographs (Digora, Soredex, Helsinki, Finland) were taken with a long-cone, parallel technique at abutment connection, loading, 1-, 3-, and 5-year follow-ups. Measurements were performed under $7\times$ magnification by one and the same examiner (MR), who was blinded for the implant surface.

2.4 | Clinical parameters (secondary outcome variables)

Probing pocket depth (PPD), gingival recessions (REC, relative to the restoration-abutment junction), and bleeding on probing (BoP, present = 1, absent = 0) were recorded at six sites per implant with a periodontal probe (XP23 15; HuFriedy, Chicago, IL, USA), and mean values per implant were calculated. The clinical attachment level (CAL) was also calculated (formula: PPD + REC – abutment length). To estimate the evolution of clinical parameters, data from earlier analyses were included.

At the 5-year follow-up, the incidence of peri-implantitis was estimated, using the following criteria: PPD ≥ 5 mm + BoP + radiographic bone loss ≥ 2.5 mm (baseline = loading).

2.5 | Microbial sampling (tertiary outcome variables)

Subgingival plaque samples were collected at the beginning of several visits (14-day, 3-month, 1-year, 3-year, and 5-year follow-up). For more details, see Quirynen & Van Assche, 2012.

2.6 | Microbiological processing

For this study, all samples were re-analysed with for each patient all the samples in the same qPCR run. In summary, DNA was extracted with InstaGene matrix (Bio-Rad Life Science Research, Hercules, CA, USA). As a standard for the qPCR, a fragment of the 16S rRNA gene of *Tannerella forsythia* ATCC 43037, *Porphyromonas gingivalis* ATCC33277, *Actinobacillus actinomycetemcomitans* ATCC43718, and *Prevotella intermedia* ATCC 25611 was amplified with primers flanking the annealing site of the qPCR primers. This fragment was ligated into the pGEM-T easy vector system (Promega, Madison, WI, USA) and used to transform *Escherichia coli* DH5a. Plasmids were isolated from the clones using the High Pure Plasmid Isolation Kit (Roche Diagnostics GmbH, Mannheim, Germany). The concentration of the plasmid was determined using the GeneQuant (Amersham Pharmacia Biotech, Roosendaal, The Netherlands) at a wavelength of 260 nm. Primers and probes were synthesized by Eurogentec (Seraing, Belgium). qPCR was performed on the CFX96 Real-Time System (Bio-Rad, Temse, Belgium). Data were collected during each annealing phase. In each run, template controls were included. Results were expressed in log₁₀ Genome Equivalents (Geq)/ml or number of bacterial genome/ml. For more details, see Quirynen & Van Assche, 2012.

2.7 | Statistical analysis

The implant was the statistical unit in all analyses regarding marginal bone loss, CAL, BoP, and the microbiological parameters. For the comparison between partially and fully edentulous patients, the patient was the statistical unit. Inferential statistics were performed using non-parametric Mann-Whitney *U* tests. The level of significance was set to 0.05. To adjust for multiple comparisons, a Bonferroni correction was applied. This led to a corrected significance level of $p = .01$. The comparison between Tur and TiU implants concerning the incidence of peri-implantitis was performed via a Chi-square test.

3 | RESULTS

This 5-year report includes 15 of the initial group of 18 patients. Their mean age at implant insertion was 64 years (range: 46–72). Six patients were partial edentulous (5 males, 2 smokers, with 1 overdenture and 5 fixed full bridges, all in the upper jaw), and 9 were full edentulous (6 males, 1 smoker, with 3 fixed full bridges in the lower jaw, 2 overdentures in the upper jaw, and 4 patients with an overdenture in both the upper and lower jaw). In these 15 patients, initially 84 implants were placed, 42 with a TiU and 42 with a Tur surface. One Tur implant showed an early failure and was removed at abutment connection. The cumulative survival rate at the 5-year follow-up was 97.6% for Tur and 100% for TiU implants.

The periodontal condition of the remaining teeth in the partial edentulous group was, in summary: full mouth plaque score $>15\%$ in

TABLE 1 Clinical parameters, measured at different times/time intervals, grouped per implant surface (Tur/TiU) or per subgroup (partial/full edentulism)

Bone level at loading and bone level changes over different time intervals (– values = bone loss)										
Time/time interval	Tur implants		TiU implants		p-Value	Full edentulous		Partial edentulous		p-Value
	Mean	SD	Mean	SD		Mean	SD	Mean	SD	
Abutment connection										
Loading	–1.82	0.62	–1.85	0.80	.85	–1.54	0.63	–2.25	0.62	.00
Loading–1 year	–0.36	0.42	–0.40	0.46	.39	–0.34	0.33	–0.43	0.56	.70
Loading–3 years	–0.71	0.66	–0.94	0.69	.09	–0.69	0.61	–1.01	0.74	.04
Loading–5 years	–1.00	0.90	–1.65	1.65	.06	–0.95	0.98	–1.84	1.64	.00
Pocket probing depth at years 1, 3 and 5 (mean of 6 measurements/implant)										
Time/time interval	Tur implants		TiU implants		p-Value	Full edentulous		Partial edentulous		p-Value
	Mean	SD	Mean	SD		Mean	SD	Mean	SD	
Year 1	3.04	1.12	3.26	1.21	.31	2.60	0.64	4.05	1.29	.00
Year 3	3.20	1.40	3.66	1.89	.52	2.71	0.79	4.63	2.04	.00
Year 5	3.09	1.01	4.19	2.61	.09	2.79	0.92	4.87	2.57	.00
Attachment loss at years 1 and 5 (+ values = apical to implant/abutment junction)										
Time/time interval	Tur implants		TiU implants		p-Value	Full edentulous		Partial edentulous		p-Value
	Mean	SD	Mean	SD		Mean	SD	Mean	SD	
Year 1	0.75	1.19	1.07	1.47	.25	0.37	1.13	1.82	1.18	.00
Year 5	0.51	1.40	1.66	2.80	.10	0.20	0.94	2.37	2.96	.00
Bleeding on probing at years 1, 3 and 5 (number of bleeding sites, 6 scores/implant)										
Time/time interval	Tur implants		TiU implants		p-Value	Full edentulous		Partial edentulous		p-Value
	Mean	SD	Mean	SD		Mean	SD	Mean	SD	
Year 1	1.68	2.46	1.38	2.16	.75	0.90	1.74	2.58	2.76	.00
Year 3	2.04	2.10	2.58	2.40	.33	1.15	1.92	3.66	2.10	.00
Year 5	2.76	2.52	3.78	2.28	.04	2.22	2.10	4.74	2.16	.00

Comparisons between implant surfaces = on implant level, between full and partial edentulous patients = on patient level.

5/6 patients, full-mouth bleeding score >15% in 4/6 patients, number of teeth with PPD >4 mm and BoP (teeth/total number of teeth) per patient: 0/11, 0/14, 3/15, 3/10, 5/12, 8/8 teeth, respectively.

3.1 | Bone level changes

During the first 5 years of loading, a significant amount of marginal bone loss was observed (0.4, 0.8 and 1.3 mm at year 1, 3 and 5, respectively, Table 1). This loss was slightly higher for TiU than for Tur surfaces (1.7 ± 1.7 mm versus 1.0 ± 0.9 mm, respectively, $p = .06$), and especially higher in partially compared to fully edentulous patients (1.8 ± 1.6 mm versus 1.0 ± 1.0 mm, respectively, $p = .001$).

The difference between Tur and TiU surfaces was more obvious in the partially edentulous subgroup (1.2 mm, $p = .05$) than in fully edentulous subgroup (0.3 mm, $p = .36$). Within the TiU surface group the difference between partially and fully edentulous patients was more pronounced (1.3 mm) than within the Tur surface group (0.5 mm).

For most patients, the difference between TiU and Tur (Figure 1) remained small, but for some of them, this difference was clinically relevant (Figure 1). During the 5 years of loading, 3/41 Tur and 12/42 TiU implants lost more than 2.5 mm bone.

3.2 | Clinical parameters

3.2.1 | PPD

The PPD values slowly increased over time (3.2, 3.4 and 3.6 mm at years 1, 3 and 5, respectively, Table 1). At the 5-year follow-up, there was no clear difference ($p = .089$) between Tur (3.1 ± 1.0 mm) and TiU (4.2 ± 2.6 mm) surfaces; however, the number of implants with a mean PPD >5 mm was higher for TiU implants (Figure 2 9/42 for TiU versus 2/41 for Tur).

The PPD values were significantly higher for partially edentulous subgroup (1.9 versus 2.8 mm, respectively, $p = .001$). The difference

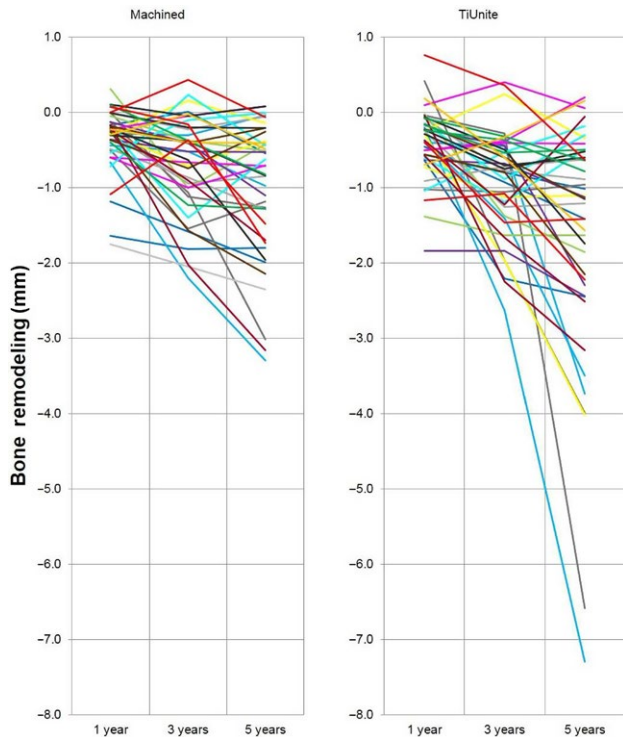


FIGURE 1 Bone remodelling per implant (in mm, raw data) as observed after 1, 3 and 5 years, for the Tur and TiU surfaces, respectively. Different colours represent different patients

in PPD between both surfaces was higher for partially edentulous patients (2.1 mm) than fully edentulous patients (0.4 mm). When evaluating each surface per subgroup, the difference between partially and fully edentulous patients within the TiU surface group was more pronounced (2.9 mm) than that in the Tur surface group (1.2 mm).

3.2.2 | CAL

At the 5-year follow-up, a significant amount of attachment loss could be recorded (1.1 ± 2.1 mm). The amount of attachment loss was 1.1 mm higher ($p = .06$) for TiU surface implants (Table 1). Significant more attachment loss was recorded for partially than for fully edentulous patients (2.4 ± 3.0 mm versus 0.20 ± 0.9 mm, respectively, $p = .001$). The number of implants with a mean attachment loss ≥ 3 mm was higher for TiU implants (8/42 for TiU versus 2/41 for Tur).

3.2.3 | BoP

The mean number of sites with BoP slightly increased over time (1.5 versus 2.3 versus 3.3 at year 1, 3 and 5, respectively) (Table 1). The BoP values were at the 5-year follow-up significantly higher for TiU surfaces (3.8 versus 2.8, respectively). More BoP was recorded for partially than for fully edentulous patients (4.7 ± 2.2 versus 2.2 ± 2.1 , respectively, $p = .001$). The BoP scores were worse for TiU surfaces than for Tur surfaces, in both fully and partially edentulous patients (mean difference: 1.1 for each subgroup). When evaluating each surface separately, partially edentulous

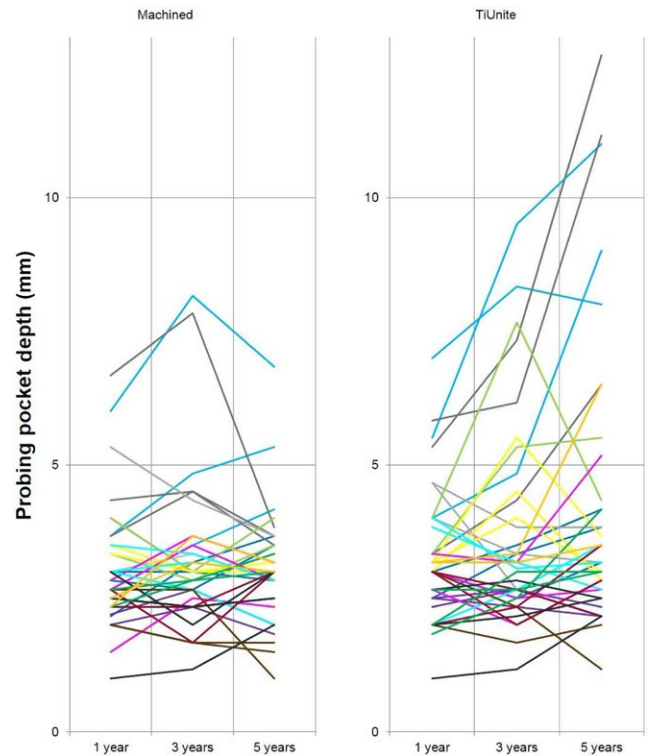


FIGURE 2 Probing pocket depth per implant (in mm, raw data) as observed after 1, 3 and 5 years, for the Tur and TiU surfaces, respectively. Different colours represent different patients

patients always had higher bleeding values than fully edentulous patients.

3.3 | Peri-implantitis

After 5 years, 3 Tur and 12 TiU implants were diagnosed with peri-implantitis ($p < .01$). The latter occurred less in fully edentulous (1/48 implants) compared with partially edentulous patients (14/35 implants, $p < .01$).

3.4 | Microbiology

At the 5-year follow-up, no significant differences were found between different implant surfaces or between subgroups for the counts of *A. actinomycetemcomitans*, *P. gingivalis*, *P. intermedia*, or *T. forsythia* based on qPCR. Moreover, *A. actinomycetemcomitans* and *P. intermedia* were not frequently detected. The boxplots of the qPCR data showed small differences in *P. gingivalis* count between partially and fully edentulous patients and in *A. actinomycetemcomitans* count between the TiU and Tur surfaces (Figures 3 and 4). No statistically significant differences could be demonstrated.

4 | DISCUSSION

The mean marginal bone loss during 5 years of loading in this study was 1.3 mm, which is higher than that shown in most studies. Our

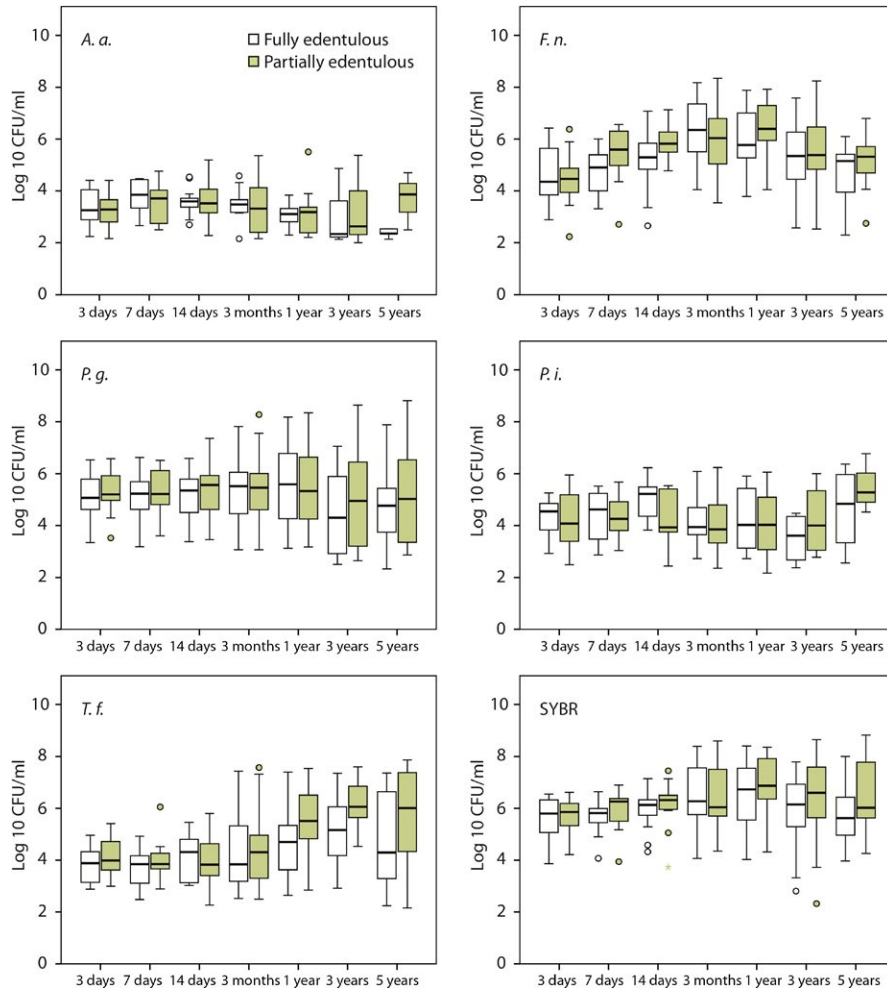


FIGURE 3 Microbial changes (qPCR technology) over time (3, 7 and 14 days, 3 months after abutment connection, and 1, 3 and 5 years after loading) in partially and fully edentulous patients. Data are presented via Whisker box plots

data might be explained by the fact that all included patients suffered from generalized severe periodontitis with a high periodontal risk profile (Lang & Tonetti, 2003). Moreover, in the partial edentulous group, some residual pockets (4–6 mm) were still present at implant/abutment insertion. After implant installation, patients were enrolled in a maintenance programme with annual recall visits. In retrospect, the frequency of these recall visits should have been higher. A high number of patients (7 of 15) did even not comply with annual recall visits, most of them only came at year 1, 3 and 5. The importance of a strict maintenance protocol to guarantee stable bone levels for patients with a history of periodontitis is highlighted in several papers (Pjetursson et al., 2012; Rocuzzo et al., 2012; Van Assche et al., 2012). Several patients had a poor oral hygiene, another risk factor for peri-implant disease (Serino & Ström, 2009). Smoking (also associated with peri-implantitis Mombelli et al., 2012) was recorded for three patients.

While differences in marginal bone loss between the two implant surfaces were not significant, a clear trend was observed where TiU surfaces lost more bone than Tur surfaces after 5 years of follow-up. Moreover, this difference in bone loss between Tur and TiU surfaces increases over time. A post hoc analysis revealed that if the study population had been increased by a factor of 1.99, the differences could have reached statistical significance. Some

studies found the opposite. Rocci et al. (2013) performed an RCT placing Tur and TiU implants with immediate loading in two groups of partially edentulous patients. The authors did not specify the cause for the edentulism. They found that at 9 years after loading, Tur implants lost 1.7 mm and TiU implants 1.4 mm of marginal bone. Arnhart et al. (2013) performed a retrospective analysis of fully edentulous patients with 4 Tur or TiU inter-foraminal implants. They observed that after 7 years, Tur implants had lost 2.42 mm bone, whereas TiU implants had lost 1.53 mm. Whether or not these patients were periodontally susceptible was not discussed. Watzak et al. (2006) investigated BoP and PPD around Tur and TiU implants, and found no differences between them after 33 months of loading.

Despite the above-mentioned differences, the cumulative implant survival rate in this study was 97.9%; which is comparable with that of previous studies (Friberg & Jemt, 2010; Jemt, Stenport, & Friberg, 2011; Polizzi et al., 2013; Wennström, Dahlén, Svensson, & Nyman, 1987). One Tur implant and no TiU implant were lost before loading. It is known that implants with a TiU surface have an improved initial bone response during osseointegration, leading to a better early survival rates, when compared with minimally rough surfaces (Ivanoff, Widmark, Johansson, & Wennerberg, 2003; Polizzi et al., 2013; Shibli, Feres, de Figueiredo, Iezzi, & Piattelli,

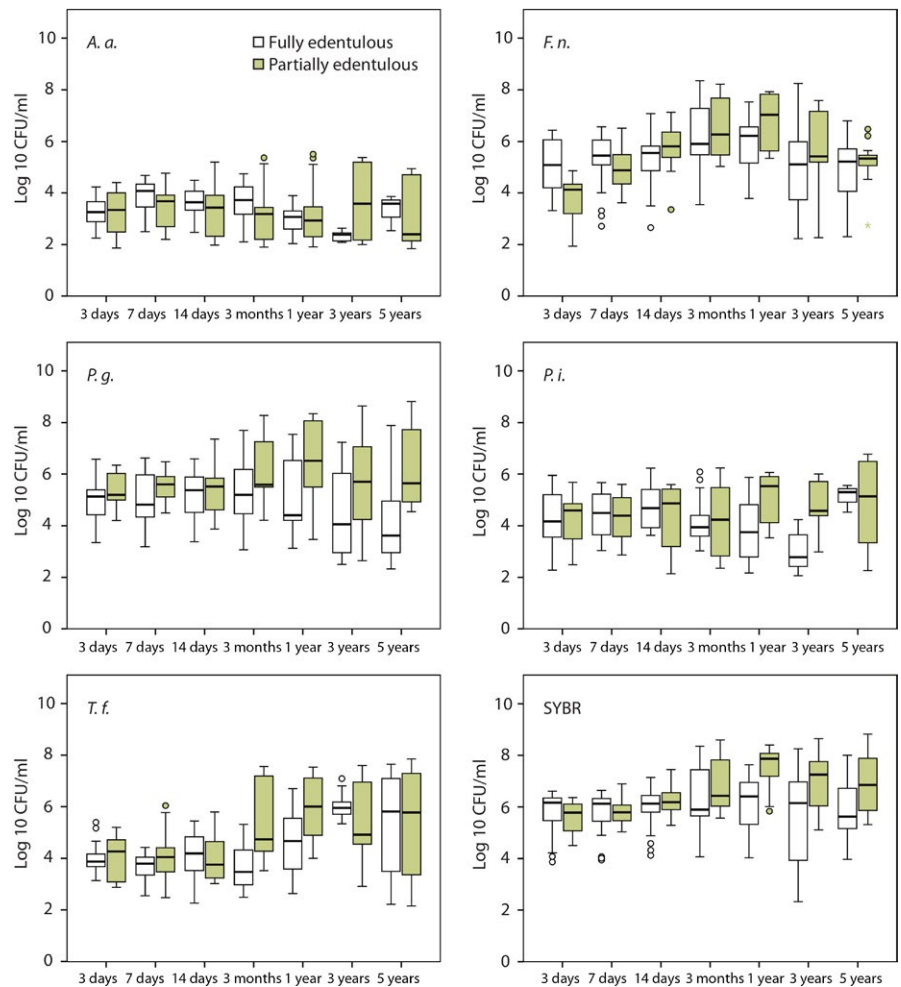


FIGURE 4 Microbial changes (qPCR technology) over time (3, 7 and 14 days, 3 months after abutment connection, and 1, 3 and 5 years after loading) for Tur and TiU implants, respectively. Data are presented via Whisker box-plots

2007). Moderately rough surfaces were introduced to improve early bone response after placement and ensure faster osseointegration as well as higher bone-to-implant contact. These characteristics of moderately rough implant surfaces have been validated in several animals, as well as in human histological studies (Al-Nawas, Groetz, Goetz, Duschner, & Wagner, 2008; Ivanoff et al., 2003; Shalabi, Gortemaker, Van't Hof, Jansen, & Creugers, 2006; Shibli et al., 2007; Sul et al., 2001; Xiropaidis et al., 2005) and clinical trials (Arnhart et al., 2013; Jemt et al., 2011; Polizzi et al., 2013; Rocci et al., 2013; Vandeweghe et al., 2016). On the other hand, one should keep in mind the negative impact of surface roughness on plaque formation (Amoroso et al. 2006; Bürgers et al., 2010; Quirynen & Bollen, 1995; Teughels et al., 2006).

Despite the good cumulative implant survival rates for both implant types, in this study, the TiU surface was more prone to peri-implant disease (in increased bone and attachment loss) than the Tur surface. For patients with severe periodontitis, this increased risk of peri-implant disease might be the price one must pay to minimize the risk of early implant failure.

The significant difference between partially and fully edentulous patients was striking. Two potential hypotheses could explain this difference. In partially edentulous patients, peri-implant microbiota resembles that of the remaining teeth within a few

days after abutment connection due to bacterial translocation (Boutaga, van Winkelhoff, Vandenbroucke-Grauls, & Savelkoul, 2005; Leonhardt, Berglundh, Ericsson, & Dahlén, 1992; Mombelli et al., 1995; van Winkelhoff, Goené, Benschop, & Folmer, 2000). Machtei and Hirsch (2007) described how retention of hopeless teeth can be achieved by maintaining deep periodontal pockets without a compromising effect on neighbouring teeth. It seems contradictory that maintaining deep periodontal pockets, and thus higher numbers of periopathogens, in the mouth has no compromising effect on other teeth but seems to have a compromising effect on implants. Another hypothesis could be that the remaining periodontally involved teeth sustain a level of inflammation, thereby priming the host for an exaggerated response to bacterial insults on peri-implant tissues and thus causing tissue damage. The reason why fully edentulous patients seem to be more resistant to peri-implant tissue destruction remains unclear and requires further investigation.

The microbiological data in this study showed no significant differences between implant surfaces in qPCR data for specific periopathogens.

The data presented in this study should be considered in view of the limitations of the study. As mentioned before, the number of patients in the study is rather limited and this might have influenced

the statistical power of the study. However, for many parameters, the data are flirting with statistical significance indicating clear trends. Additionally, one should consider that the partially edentulous patients might not reflect the ideal periodontally compromised patient since their periodontal condition cannot be considered as optimal and supportive periodontal therapy was often not respected or could be improved. Also, the use of TiU abutments does not reflect daily reality. Despite these shortcomings, some conclusions can be drawn from the study.

5 | CONCLUSION

In conclusion, this 5-year prospective study performed in patients with a history of severe periodontitis, showed a clear difference in the outcome of implants in partially or fully edentulous patients. Partially edentulous patients were at higher risk of developing peri-implantitis, and within the partially edentulous patients, TiU surfaces showed more bone loss than Tur surfaces. The Tur implant surfaces in these patients had a lower survival (early failure) rate but otherwise showed more favourable clinical results, with respect to hard- and soft-tissue response. Also, on a microbiological level, TiU surfaces showed more pathogenic microbiota; however, this difference was statistically insignificant; therefore, hard conclusions on the microbiology around TiU implants based on the present data are not possible.

ACKNOWLEDGEMENTS

The Catholic University of Leuven, University Hospitals & Dentistry Leuven, Periodontology, Belgium, supported the study, partially. The authors thank Rahel Meister, Nobel Biocare Services AG, for his support in statistical analysis and preparation of the graphs.

CONFLICT OF INTEREST

The authors have stated explicitly that there are no conflicts of interest in connection with this article.

ORCID

Magalie Raes  <http://orcid.org/0000-0001-8263-8363>

Wim Teughels  <http://orcid.org/0000-0001-7675-5643>

REFERENCES

- Albrektsson, T., & Wennerberg, A. (2004). Oral implant surfaces: Part I – Review focusing on topographic and chemical properties of different surfaces and in vivo responses to them. *International Journal of Prosthodontics*, *17*, 536–543.
- Al-Nawas, B., Groetz, K. A., Goetz, H., Duschner, H., & Wagner, W. (2008). Comparative histomorphometry and resonance frequency analysis of implants with moderately rough surfaces in a loaded animal model. *Clinical Oral Implants Research*, *19*, 1–8.
- Alsaadi, G., Quirynen, M., Michiles, K., Teughels, W., Komarek, A., & van Steenberghe, D. (2008). Impact of local and systemic factors on the incidence of failures up to abutment connection with modified surface oral implants. *Journal of Clinical Periodontology*, *35*, 51–57.
- Amoroso, P. F., Adams, R. J., Waters, M. G., & Williams, D. W. (2006). Titanium surface modification and its effect on the adherence of *Porphyromonas gingivalis*: An in vitro study. *Clinical Oral Implants Research*, *17*(6), 633–637. Erratum in: *Clin Oral Implants Res.* 2009 Jun;20(6):643. Pier-Francesco, Amoroso [corrected to Amoroso, Pier Francesco]. PubMed PMID: 17092220.
- Aoki, M., Takanashi, K., Matsukubo, T., Yajima, Y., Okuda, K., Sato, T., & Ishihara, K. (2012). Transmission of periodontopathic bacteria from natural teeth to implants. *Clinical Implant Dentistry and Related Research*, *14*, 406–411. <https://doi.org/10.1111/j.1708-8208.2009.00260.x>
- Apse, P., Ellen, R. P., Overall, C. M., & Zarb, G. A. (1989). Microbiota and crevicular fluid collagenase activity in the osseointegrated dental implant sulcus: A comparison of sites in edentulous and partially edentulous patients. *Journal of Periodontal Research*, *24*, 96–105. <https://doi.org/10.1111/j.1600-0765.1989.tb00863.x>
- Arnhart, C., Dvorak, G., Trefil, C., Huber, C., Watzek, G., & Zechner, W. (2013). Impact of implant surface topography: A clinical study with a mean functional loading time of 85 months. *Clinical Oral Implants Research*, *24*, 1049–1054.
- Berglundh, T., Gotfredsen, K., Zitzmann, N. U., Lang, N. P., & Lindhe, J. (2007). Spontaneous progression of ligature induced peri-implantitis at implants with different surface roughness: An experimental study in dogs. *Clinical Oral Implants Research*, *18*, 655–661. <https://doi.org/10.1111/j.1600-0501.2007.01397.x>
- Bernard, J. P., Szmukler-Moncler, S., Pessotto, S., Vazquez, L., & Belsler, U. C. (2003). The anchorage of Brånemark and ITI implants of different lengths. I. An experimental study in the canine mandible. *Clinical Oral Implants Research*, *14*, 593–600. <https://doi.org/10.1034/j.1600-0501.2003.120908.x>
- Boutaga, K., van Winkelhoff, A. J., Vandenbroucke-Grauls, C. M., & Savelkoul, P. H. (2003). Comparison of real-time PCR and culture for detection of *Porphyromonas gingivalis* in subgingival plaque samples. *Journal of Clinical Microbiology*, *41*, 4950–4954. <https://doi.org/10.1128/JCM.41.11.4950-4954.2003>
- Bürgers, R., Gerlach, T., Hahnel, S., Schwarz, F., Handel, G., & Gosau, M. (2010). In vivo and in vitro biofilm formation on two different titanium implant surfaces. *Clinical Oral Implants Research*, *21*, 156–164. <https://doi.org/10.1111/j.1600-0501.2009.01815.x>
- Daubert, D. M., Weinstein, B. F., Bordin, S., Leroux, B. G., & Flemming, T. F. (2015). Prevalence and predictive factors for peri-implant disease and implant failure: A cross-sectional analysis. *Journal of Periodontology*, *86*, 337–347. <https://doi.org/10.1902/jop.2014.140438>
- Esposito, M., Grusovin, M. G., Coulthard, P., Thomsen, P., & Worthington, H. V. (2005). A 5-year follow-up comparative analysis of the efficacy of various osseointegrated dental implant systems: A systematic review of randomized controlled clinical trials. *The International Journal of Oral & Maxillofacial Implants*, *20*, 557–568.
- Friberg, B., & Jemt, T. (2010). Clinical experience of TiUnite implants: A 5-year cross-sectional, retrospective follow-up study. *Clinical Implant Dentistry and Related Research*, *12*, e95–e103.
- Fürst, M. M., Salvi, G. E., Lang, N. P., & Persson, G. R. (2007). Bacterial colonization immediately after installation on oral titanium implants. *Clinical Oral Implants Research*, *18*, 501–508. <https://doi.org/10.1111/j.1600-0501.2007.01381.x>
- Glauser, R., Schüpbach, P., Gottlow, J., & Hämmerle, C. H. (2005). Periimplant soft tissue barrier at experimental one-piece mini-implants with different surface topography in humans: A light-microscopic overview and histometric analysis. *Clinical Implant Dentistry and Related Research*, *7*(Suppl. 1), 544–551.

- Hardt, C. R., Gröndahl, K., Lekholm, U., & Wennström, J. L. (2002). Outcome of implant therapy in relation to experienced loss of periodontal bone support. A retrospective 5-year study. *Clinical Oral Implants Research*, 13, 488–494. <https://doi.org/10.1034/j.1600-0501.2002.130507.x>
- Hultin, M., Fischer, J., Gustafsson, A., Kallus, T., & Klinge, B. (2000). Factors affecting late fixture loss and marginal bone loss around teeth and dental implants. *Clinical Implant Dentistry and Related Research*, 2, 203–208. <https://doi.org/10.1111/j.1708-8208.2000.tb00118.x>
- Ivanoff, C. J., Widmark, G., Johansson, C., & Wennerberg, A. (2003). Histologic evaluation of bone response to oxidized and turned titanium micro-implants in human jawbone. *The International Journal of Oral & Maxillofacial Implants*, 18, 341–348.
- Jemt, T., Stenport, V., & Friberg, B. (2011). Implant treatment with fixed prostheses in the edentulous maxilla. Part 1: Implants and biologic response in two patient cohorts restored between 1986 and 1987 and 15 years later. *The International Journal of Prosthodontics*, 24, 345–355.
- Jungner, M., Lundqvist, P., & Lundgren, S. (2005). Oxidized titanium implants (Nobel Biocare TiUnite) compared with turned titanium implants (Nobel Biocare mark III) with respect to implant failure in a group of consecutive patients treated with early functional loading and two-stage protocol. *Clinical Oral Implants Research*, 16, 308–312. <https://doi.org/10.1111/j.1600-0501.2005.01101.x>
- Karoussis, I. K., Kotsivilis, S., & Fourmouis, I. (2007). A comprehensive and critical review of dental implant prognosis in periodontally compromised partially edentulous patients. *Clinical Oral Implants Research*, 18, 669–679. <https://doi.org/10.1111/j.1600-0501.2007.01406.x>
- Koh, J. W., Yang, J. H., Han, J. S., Lee, J. B., & Kim, S. H. (2009). Biomechanical evaluation of dental implants with different surfaces: Removal torque and resonance frequency analysis in rabbits. *The Journal of Advanced Prosthodontics*, 1, 107–112. <https://doi.org/10.4047/jap.2009.1.2.107>
- Lang, N. P., Berglundh, T., & Working Group 4 of Seventh European Workshop on Periodontology. (2011). Periimplant diseases: Where are we now? – Consensus of the Seventh European Workshop on Periodontology. *Journal of Clinical Periodontology*, 38(Suppl. 11), 178–181. <https://doi.org/10.1111/j.1600-051X.2010.01674.x>
- Lang, N. P., & Tonetti, M. S. (2003). Periodontal risk assessment (PRA) for patients in supportive periodontal therapy (SPT). *Oral Health & Preventative Dentistry*, 1, 7–16.
- Leonhardt, A., Berglundh, T., Ericsson, I., & Dahlén, G. (1992). Putative periodontal and teeth in pathogens on titanium implants and teeth in experimental gingivitis and periodontitis in beagle dogs. *Clinical Oral Implants Research*, 3, 112–119. <https://doi.org/10.1034/j.1600-0501.1992.030303.x>
- Lindquist, L. W., Carlsson, G. E., & Jemt, T. (1996). A prospective 15-year follow-up study of mandibular fixed prostheses supported by osseointegrated implants. Clinical results and marginal bone loss. *Clinical Oral Implants Research*, 7, 329–336. <https://doi.org/10.1034/j.1600-0501.1996.070405.x>
- Machtei, E. E., & Hirsch, I. (2007). Retention of hopeless teeth: The effect on the adjacent proximal bone following periodontal surgery. *Journal of Periodontology*, 78, 2246–2252. <https://doi.org/10.1902/jop.2007.070125>
- Mishler, O. P., & Shiau, H. J. (2014). Management of peri-implant disease: A current appraisal. *The Journal of Evidence-Based Dental Practice*, 14(Suppl.), 53–59. <https://doi.org/10.1016/j.jebdp.2014.04.010>
- Mombelli, A., Marxer, M., Gaberthüel, T., Grunder, U., & Lang, N. P. (1995). The microbiota of osseointegrated implants in patients with a history of periodontal disease. *Journal of Clinical Periodontology*, 22, 124–130.
- Mombelli, A., Müller, N., & Cionca, N. (2012). The epidemiology of peri-implantitis. *Clinical Oral Implants Research*, 23(Suppl. 6), 67–76. <https://doi.org/10.1111/j.1600-0501.2012.02541.x>
- Nicu, E., Van Assche, N., Coucke, W., Teughels, W., & Quirynen, M. (2012). RCT comparing implants with turned and anodically oxidized surfaces: A pilot study, a 3-year follow-up. *Journal of Clinical Periodontology*, 39, 1183–1190. <https://doi.org/10.1111/jcpe.12022>
- Ong, C. T., Ivanovski, S., Needleman, L. G., Retzepi, M., Moles, D. R., Tonetti, M. S., & Donos, N. (2008). Systematic review of implant outcomes in treated periodontitis subjects. *Journal of Clinical Periodontology*, 35, 438–462. <https://doi.org/10.1111/j.1600-051X.2008.01207.x>
- Pjetursson, B. E., Helbling, C., Weber, H. P., Matuliene, G., Salvi, G. E., Brägger, U., ... Lang, N. P. (2012). Peri-implantitis susceptibility as it relates to periodontal therapy and supportive care. *Clinical Oral Implants Research*, 23, 888–894. <https://doi.org/10.1111/j.1600-0501.2012.02474.x>
- Polizzi, G., Gualini, F., & Friberg, B. (2013). A two-center retrospective analysis of long-term clinical and radiologic data of TiUnite and turned implants placed in the same mouth. *The International Journal of Prosthodontics*, 26, 350–358. <https://doi.org/10.11607/ijp.3386>
- Quirynen, M., Abarca, M., Van Assche, N., Nevins, M., & van Steenberghe, D. (2007). Impact of supportive periodontal therapy and implant surface roughness on implant outcome in patients with a history of periodontitis. *Journal of Clinical Periodontology*, 34, 805–815. <https://doi.org/10.1111/j.1600-051X.2007.01106.x>
- Quirynen, M., & Bollen, C. M. (1995). The influence of surface roughness and surface-free energy on supra- and subgingival plaque formation in man. A review of the literature. *Journal of Clinical Periodontology*, 22, 1–14.
- Quirynen, M., & Van Assche, N. (2011). Microbial changes after full-mouth tooth extraction, followed by 2-stage implant placement. *Journal of Clinical Periodontology*, 38, 581–589. <https://doi.org/10.1111/j.1600-051X.2011.01728.x>
- Quirynen, M., & Van Assche, N. (2012). RCT comparing minimally with moderately rough implants. Part 2: Microbial observations. *Clinical Oral Implants Research*, 23, 625–634. <https://doi.org/10.1111/j.1600-0501.2011.02255.x>
- Quirynen, M., van der Mei, H. C., Bollen, C. M., Schotte, A., Marechal, M., Doornbusch, G. I., ... van Steenberghe, D. (1993). An in vivo study of the influence of the surface roughness of implants on the microbiology of supra- and subgingival plaque. *Journal of Dental Research*, 72(9), 1304–1309. PubMed PMID: 8395545.
- Quirynen, M., Vogels, R., Pauwels, M., Haffajee, A. D., Socransky, S. S., Uzel, N. G., & van Steenberghe, D. (2005). Initial subgingival colonization of 'pristine' pockets. *Journal of Dental Research*, 84, 340–344. <https://doi.org/10.1177/154405910508400409>
- Renvert, S., & Persson, G. R. (2009). Periodontitis as a potential risk factor for peri-implantitis. *Journal of Clinical Periodontology*, 36(Suppl. 10), 9–14. <https://doi.org/10.1111/j.1600-051X.2009.01416.x>
- Renvert, S., & Polyzois, I. (2015). Risk indicators for peri-implant mucositis: A systematic literature review. *Journal of Clinical Periodontology*, 42(Suppl. 16), S172–S186. <https://doi.org/10.1111/jcpe.12346>
- Renvert, S., & Quirynen, M. (2015). Risk indicators for peri-implantitis. A narrative review. *Clinical Oral Implants Research*, 26(Suppl. 11), 15–44. <https://doi.org/10.1111/clr.12636>
- Rinke, S., Ohl, S., Ziebolz, D., Lange, K., & Eickholz, P. (2011). Prevalence of periimplant disease in partially edentulous patients: A practice-based cross-sectional study. *Clinical Oral Implants Research*, 22, 826–833. <https://doi.org/10.1111/j.1600-0501.2010.02061.x>
- Rocci, A., Rocci, M., Rocci, C., Scoccia, A., Gargari, M., Martignoni, M., ... Sennerby, L. (2013). Immediate loading of Brånemark system TiUnite and machined-surface implants in the posterior mandible, part II: A randomized open-ended 9-year follow-up clinical trial. *The International Journal of Oral & Maxillofacial Implants*, 28, 891–895. <https://doi.org/10.11607/jomi.2397>
- Roccuzzo, M., Bonino, F., Aglietta, M., & Dalmaso, P. (2012). Ten-year results of a three arms prospective cohort study on implants in periodontally compromised patients. Part 2: Clinical results. *Clinical Oral Implants Research*, 23, 389–395. <https://doi.org/10.1111/j.1600-0501.2011.02309.x>

- Serino, G., & Ström, C. (2009). Peri-implantitis in partially edentulous patients: Association with inadequate plaque control. *Clinical Oral Implants Research*, 20, 169–174. <https://doi.org/10.1111/j.1600-0501.2008.01627.x>
- Shalabi, M. M., Gortemaker, A., Van't Hof, M. A., Jansen, J. A., & Creugers, N. H. (2006). Implant surface roughness and bone healing: A systematic review. *Journal of Dental Research*, 85, 496–500. <https://doi.org/10.1177/154405910608500603>
- Shibli, J. A., Feres, M., de Figueiredo, L. C., Izzi, G., & Piattelli, A. (2007). Histological comparison of bone to implant contact in two types of dental implant surfaces: A single case study. *Journal of Contemporary Dental Practice*, 8, 29–36.
- Sul, V. T., Johansson, C. B., Jeong, V., Röser, K., Wennerberg, A., & Albrektsson, T. (2001). Oxidized implants and their influence on the bone response. *Journal of Materials Science Materials in Medicine*, 12, 1025–1031. <https://doi.org/10.1023/A:1012837905910>
- Teughels, W., Van Assche, N., Slieden, I., & Quirynen, M. (2006). Effect of material characteristics and/or surface topography on biofilm development. *Clinical Oral Implants Research*, 17(Suppl. 2), 68–81. <https://doi.org/10.1111/j.1600-0501.2006.01353.x>
- Van Assche, N., Coucke, W., Teughels, W., Naert, I., Cardoso, M. V., & Quirynen, M. (2012). RCT comparing minimally with moderately rough implants. Part 1: Clinical observations. *Clinical Oral Implants Research*, 23, 617–624. <https://doi.org/10.1111/j.1600-0501.2011.02256.x>
- Van der Weijden, G. A., van Bommel, K. M., & Renvert, S. (2005). Implant therapy in partially edentulous, periodontally compromised patients: A review. *Journal of Clinical Periodontology*, 32, 506–511. <https://doi.org/10.1111/j.1600-051X.2005.00708.x>
- Vandeweghe, S., Ferreira, D., Vermeersch, L., Mariën, M., & De Bruyn, H. (2016). Long-term retrospective follow-up of turned and moderately rough implants in the edentulous jaw. *Clinical Oral Implants Research*, 27, 421–426. <https://doi.org/10.1111/clr.12602>
- Watzak, G., Zechner, W., Busenlechner, D., Arnhart, C., Gruber, R., & Watzek, G. (2006). Radiological and clinical follow-up of machined- and anodized-surface implants after mean functional loading for 33 months. *Clinical Oral Implants Research*, 17, 651–657. <https://doi.org/10.1111/j.1600-0501.2006.01275.x>
- Wennerberg, A., & Albrektsson, T. (2010). On implant surfaces: A review of current knowledge and opinions. *The International Journal of Oral & Maxillofacial Implants*, 25, 63–74.
- Wennström, J. L., Dahlén, G., Svensson, J., & Nyman, S. (1987). *Actinobacillus actinomycetemcomitans*, *Bacteroides gingivalis* and *Bacteroides intermedius*: Predictors of attachment loss? *Oral Microbiology and Immunology*, 2, 158–162. <https://doi.org/10.1111/j.1399-302X.1987.tb00300.x>
- van Winkelhoff, A. J., Goené, R. J., Benschop, C., & Folmer, T. (2000). Early colonization of dental implants by putative periodontal pathogens in partially edentulous patients. *Clinical Oral Implants Research*, 11, 511–520. <https://doi.org/10.1034/j.1600-0501.2000.011006511.x>
- Xiropaidis, A. V., Qahash, M., Lim, W. H., Shanaman, R. H., Rohrer, M. D., Wikesjö, U. M., & Hall, J. (2005). Bone-implant contact at calcium phosphate-coated and porous titanium oxide (TiUnite)-modified oral implants. *Clinical Oral Implants Research*, 16, 532–539. <https://doi.org/10.1111/j.1600-0501.2005.01126.x>

How to cite this article: Raes M, D'hondt R, Teughels W, Coucke W, Quirynen M. A 5-year randomized clinical trial comparing minimally with moderately rough implants in patients with severe periodontitis. *J Clin Periodontol*. 2018;45:711–720. <https://doi.org/10.1111/jcpe.12901>