

Summarised from *Journal of Clinical Periodontology*, Volume 51, issue 1 (January 2024), 14-23

Editor: Andreas Stavropoulos, chair, EFP scientific affairs committee

**Rapporteurs:**

Rocío Bujaldón and Ignacio Zúñiga supervised by Prof. David Herrera and Prof. Mariano Sanz

**Affiliation:**

Postgraduate programme in periodontology, Complutense University, Madrid, Spain

*study*

# Autogenous or xenogeneic bone block for widening the ridge?

**Authors:**

Giuseppe Alexandre Romito, Marcelo Augusto Fonseca, Herbert Horiuti Soares, Rafael de Oliveira Lazarin, Vitor Marques Sapata, Roger Nishiyama, Marina Clemente Conde, Christoph Hans Franz Hammerle, Frank Schwarz, Cristina Cunha Villar

## Background

Dimensional bone changes occur after tooth extraction both in anterior and posterior alveolar ridges, with the anterior region of the maxilla and its buccal bone being the most vulnerable part involved in this process. As these dimensional changes may impair implant placement and treatment planning, bone-grafting procedures prior to or simultaneous with prosthetically driven implant placement are frequently required.

When primary implant stability, simultaneous with alveolar-ridge augmentation, is difficult to achieve, and in severely atrophic edentulous ridges with non-self-contained defects, a staged bone augmentation procedure is proposed.

Although autogenous bone blocks (ABB) are considered the most trustworthy and successful grafting material, they present certain limitations, such as a high morbidity and low intraoral availability. To try to overcome these disadvantages, alternative bone-grafting materials have been proposed.

Among these, equine collagenated xenogeneic bone block (CXBB) have shown good results in preclinical and clinical studies, and have not proven to be inferior to ABB. However, longitudinal data that compare clinical outcomes of implants placed in augmented ridges using ABB or CXBB are scarce and offer limited reliability.

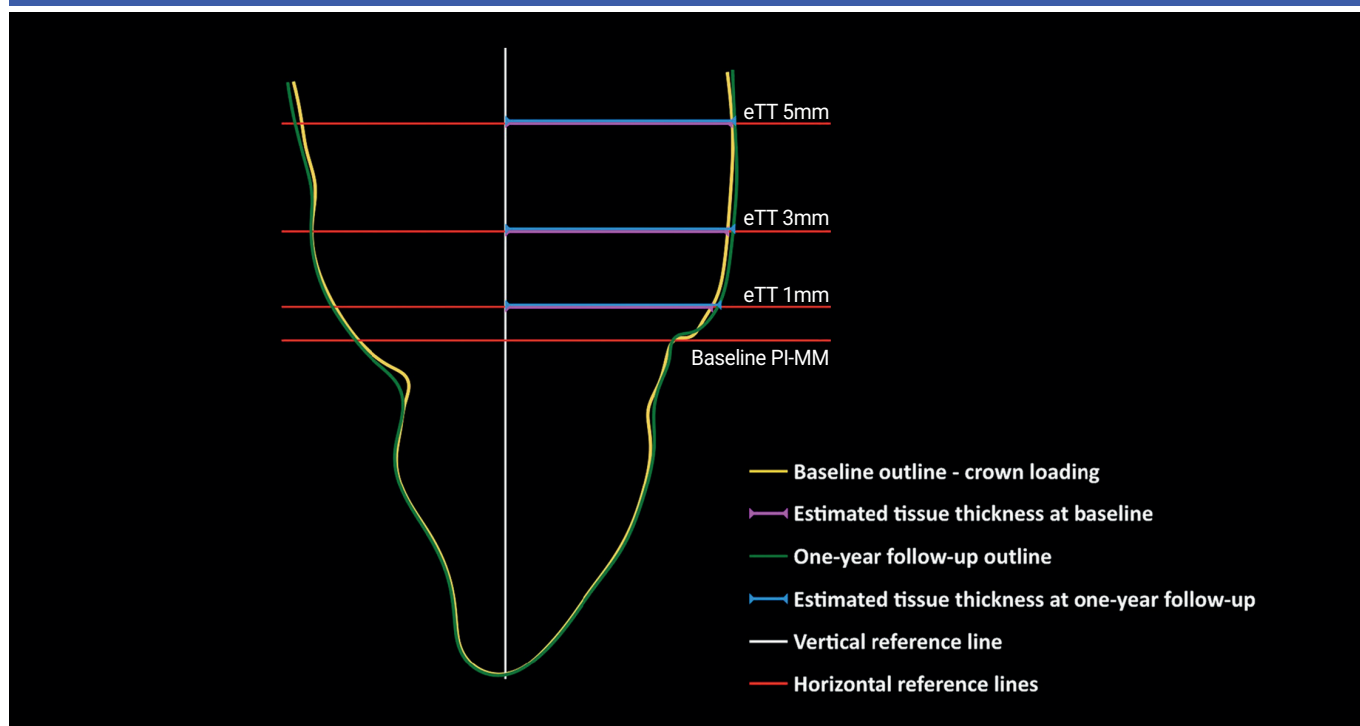
## Aim

To evaluate, as a primary objective, the survival rate of implants placed in previously augmented alveolar ridges with either ABB or CXBB after 12 months of follow-up.

## Materials & methods

- This single-centre, non-interventional study included 64 patients who underwent lateral bone augmentation before implant placement with either ABB or CXBB. Patients were recruited from a previous randomised clinical trial (RCT) performed by the same research group.
- Patients received implant placement and final screw-retained restoration 30 weeks (AAB) and 41 weeks (CXBB) after the bone-augmentation procedure. During implant placement, guided bone regeneration by means of deproteinised bovine bone mineral (DBBM) and collagen membrane (CM) was performed when needed. All implants healed submerged. Patients were enrolled in a supportive periodontal care programme according to individual needs.
- The primary outcome was implant survival, defined as the presence of the implant in the patient's mouth at the one-year follow-up, and implant success was evaluated as a secondary outcome. The follow-up examination had been scheduled for 12 months, but it was done 14.9 months after delivery of the restoration and 22.6 months after implant placement because of the global Covid-19 pandemic.
- Clinical parameters were recorded by a single calibrated investigator with a periodontal probe at six sites per implant: modified plaque index, bleeding on probing (BOP), probing depth (PD), position of the peri-implant mucosal margin, and probing attachment level. Keratinised tissue (KT) was measured at the mid-buccal site.
- Soft-tissue aesthetics around implants were evaluated according to the pink aesthetic score (PES). Optical impressions were taken at two study points – after crown loading and at the one-year follow-up visit – to estimate the soft-tissue thickness and, with this information, profilometric changes were assessed.
- Patient-reported outcome measures (PROMs), including post-operative patient discomfort and overall satisfaction with a visual analogue scale, were evaluated.

**Figure:** Schematic representation of the reference lines used for assessing tissue thickness changes



Note: Central transversal images of the target site were utilised to establish a vertical reference line (white line) parallel to the implant axis. At the baseline, a horizontal line (PI-MM) was positioned at the level of the peri-implant mucosal margin. Subsequently, three additional horizontal lines were placed 1, 3, and 5mm apical to the PI-MM reference line. To evaluate tissue thickness (eTT) and eTT changes, the distance between the vertical reference line and the buccal soft-tissue outline was measured at 1, 3, and 5mm below the peri-implant mucosal margin for each time point.

## Results

- A total of 50 implants were analysed, 28 patients in the CXBB group and 22 in the ABB group.
- Early failures occurred before abutment connection (six in the CXBB group and two in the ABB group) and no late failures occurred in either group.
- Implant survival and success rates were, respectively, 78.6% and 53.6% for the CXBB group and 90.9% and 63.6% for the ABB group. Differences between groups were not statistically significant.
- No statistically significant differences in clinical parameters were observed between the two groups. Both had approximately 50% BOP with no increase in PD. The only variable that presented a larger difference was KT, but with no significant differences between the groups.
- The PES value was slightly higher, but not statistically significant, in the ABB group (10.4), when compared to the CXBB group (8.8). Soft-tissue colour and texture received the highest scores, while the lowest scores were attributed to the papilla and the alveolar process.
- The CXBB group had a median overall increase in soft-tissue thickness of 0.2mm and the ABB group 0.2mm, with a respective mean volumetric gain of 11.3mm<sup>2</sup> and 12.5mm<sup>2</sup>.
- In terms of PROMs, the OHIP-14 questionnaire was slightly favourable in the ABB group, mainly on the variables of psychological distress and disability. Overall satisfaction scores were similar in the two groups: 85.6 in CXBB and 88.5 in ABB.

## Limitations

- The absence of statistically significant differences may be explained by the small sample size.
- No clinical data are available for patients not included in the follow-up study. Thus, selection bias may be present.
- External validity is limited because all surgical procedures were performed by a single clinician. Moreover, none of the included cases presented extensive horizontal defects, so these results cannot be extrapolated to severe cases.

## Conclusions & impact

- Staged lateral bone augmentation of atrophic alveolar ridges – either through autogenous or equine xenogeneic bone blocks – achieves outstanding survival and success rates in dental implants.
- Both groups obtained high patient-satisfaction rates, satisfactory aesthetic outcomes, and stable peri-implant conditions.
- Collagenated xenogeneic bone block graft (CXBB) can be considered as a viable clinical alternative to the use of autogenous bone block graft (ABB) in alveolar-ridge augmentation areas, and reduces patients' morbidity. Careful case selection must be performed.

JCP Digest 121, published in January 2024, is a summary of "Clinical outcomes following atrophic alveolar ridge reconstruction using collagenated xenogeneic bone block or autogenous bone block: One-year follow-up of a randomized controlled clinical". *J Clin Periodontol.* 2024; 51(01):14-23. DOI: 10.1111/jcpe13891

<https://www.onlinelibrary.wiley.com/doi/10.1111/jcpe.13891>

Access through EFP members' page log-in: <http://efp.org/members/jcp.php>